



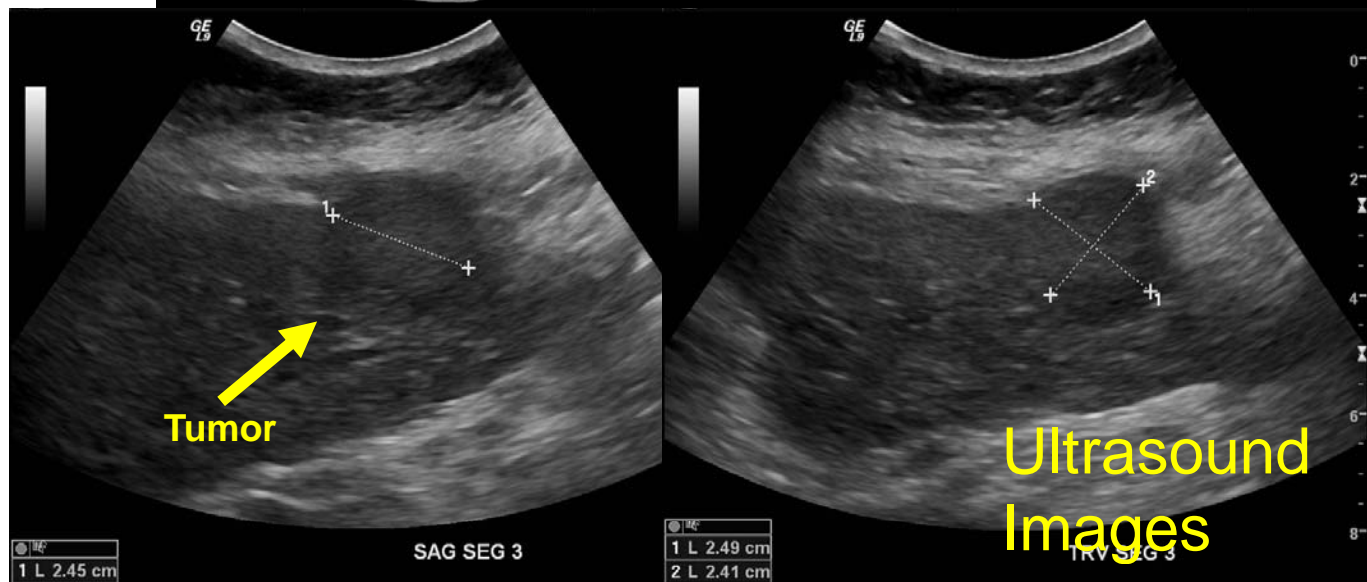
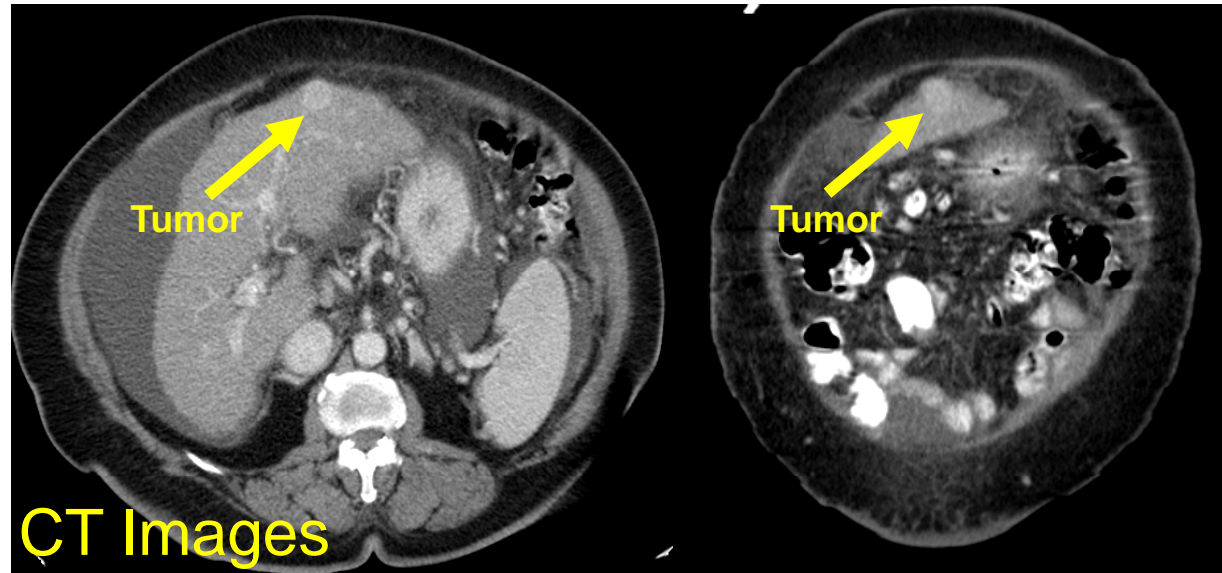
MedWaves Microwave Ablation Liver Clinical Samples



Liver Case A

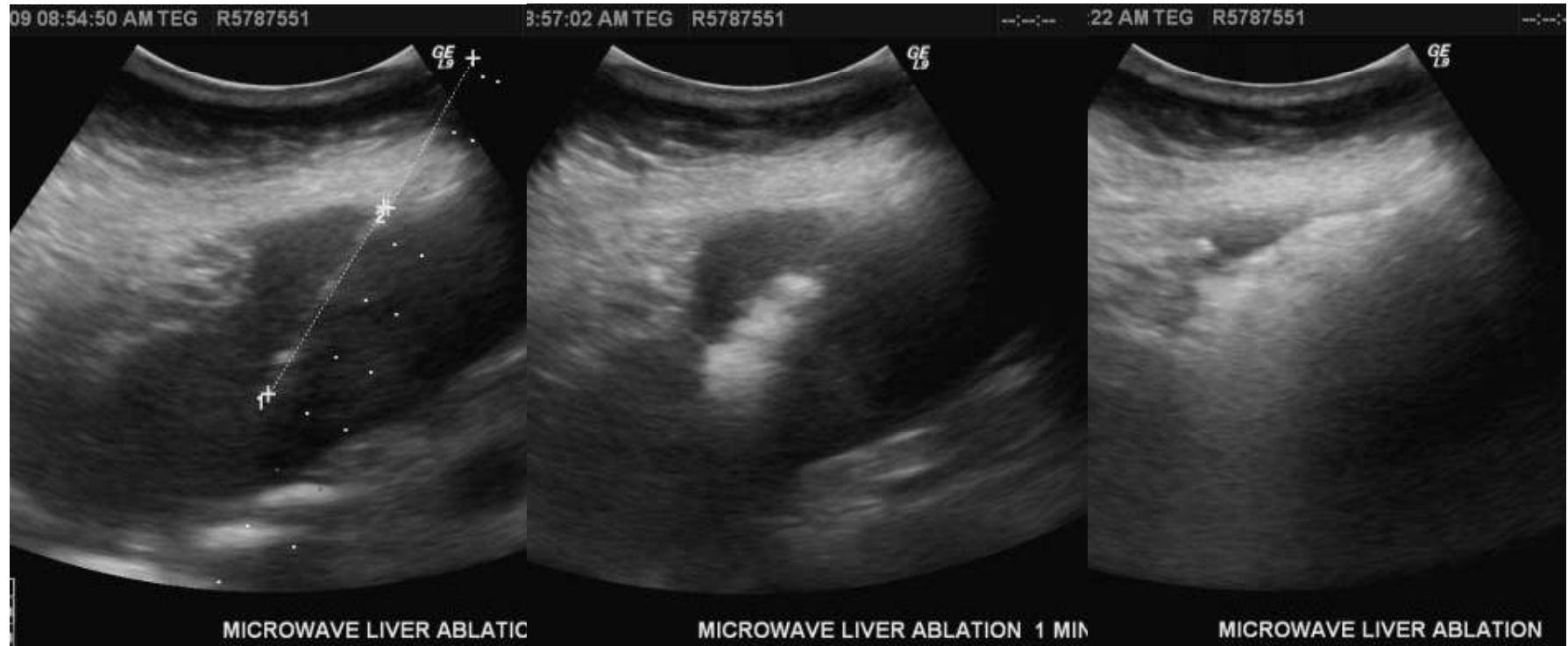Pre-ablation

- 78 year old female
- Cirrhosis
- 2.5cm HCC
- Poor surgical candidate
- Single probe
- Total 3-4 minutes of energy application
- Ultrasound image guided



Liver Case A

Ultrasound images during ablation



MW Insertion

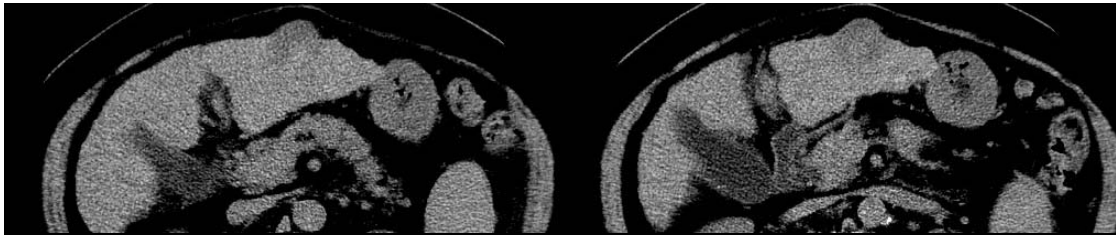
1 min of heating

2 min of heating

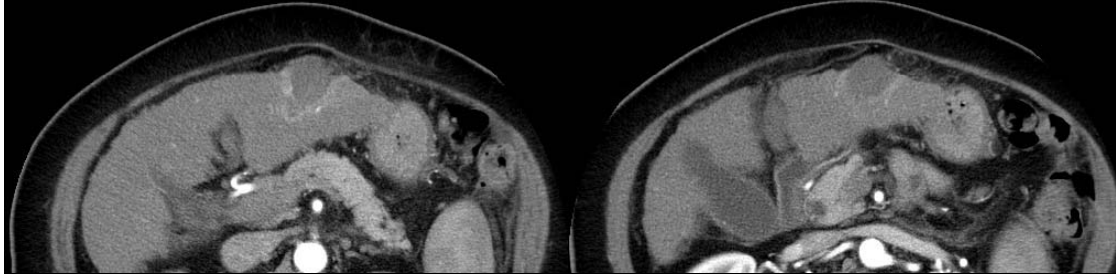
Liver Case A

Post ablation CT Contrast Images

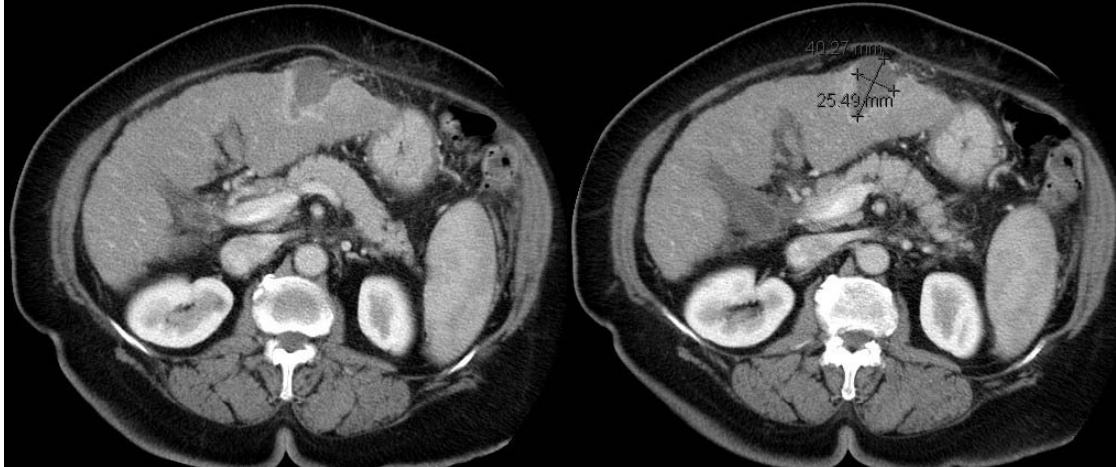
Precontrast



Arterial Phase

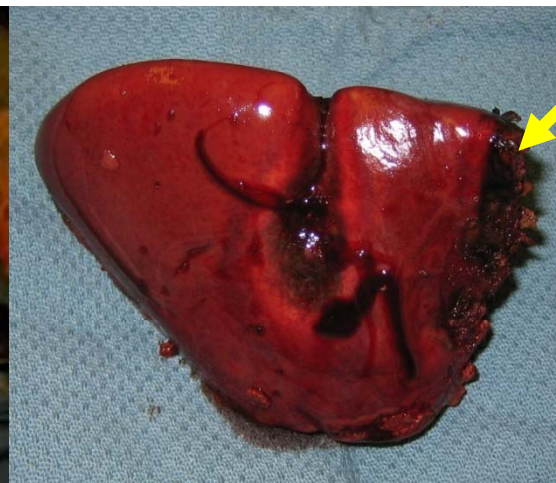
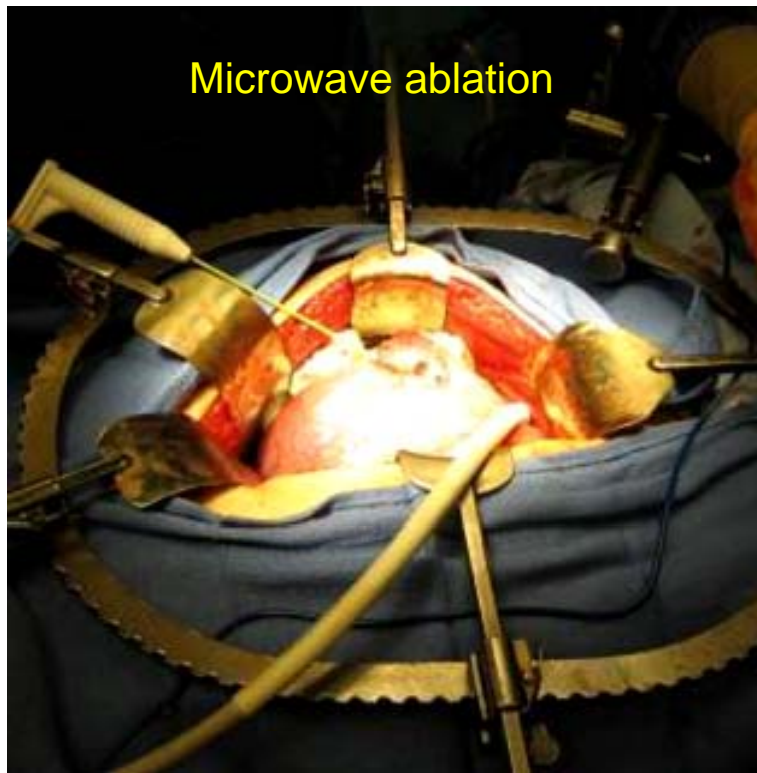

Portal Venous Phase



Liver Tumor Ablate and Resect Study

Ultrasound image guided microwave ablation with MedWaves' microwave system: 3.4cm x 3.4cm tumor



Microwave coagulated and resected surface

Stained microwave ablated tumor

Resected liver post microwaves ablation

