



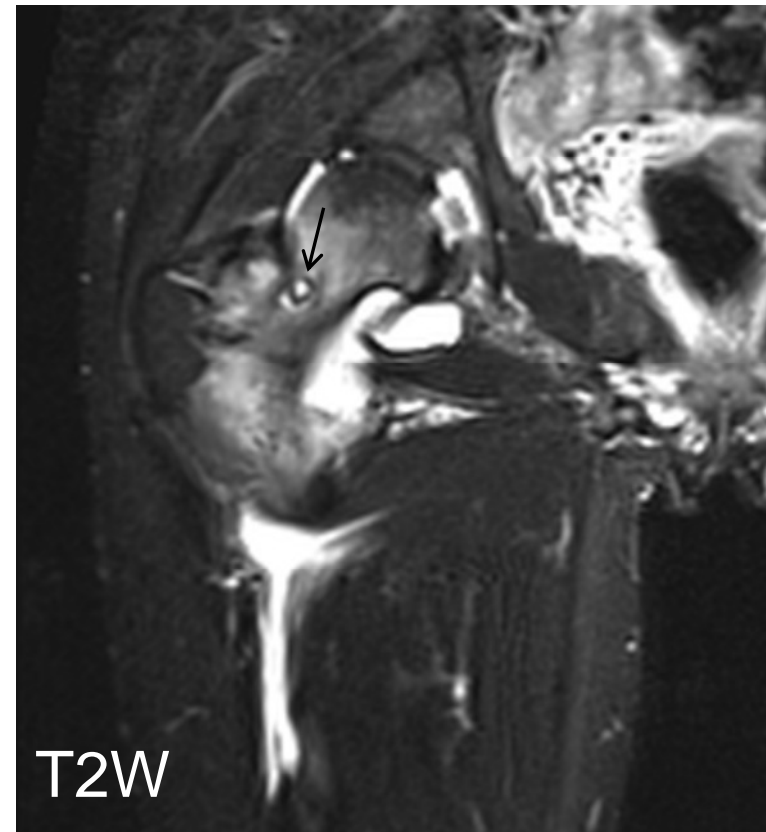
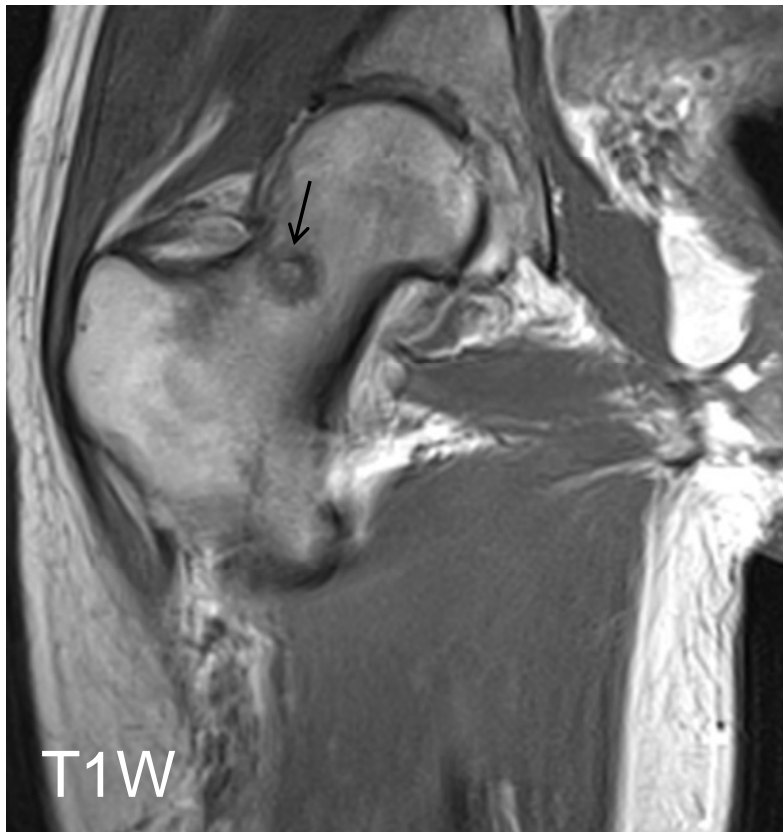# MW Ablation: Osteoid Osteoma of the Femoral Head

**Steffen J. Diehl**

Institut für Klinische Radiologie und Nuklearmedizin  
Universitätsklinikum Mannheim  
(Direktor: Prof. Dr. S. Schönberg)

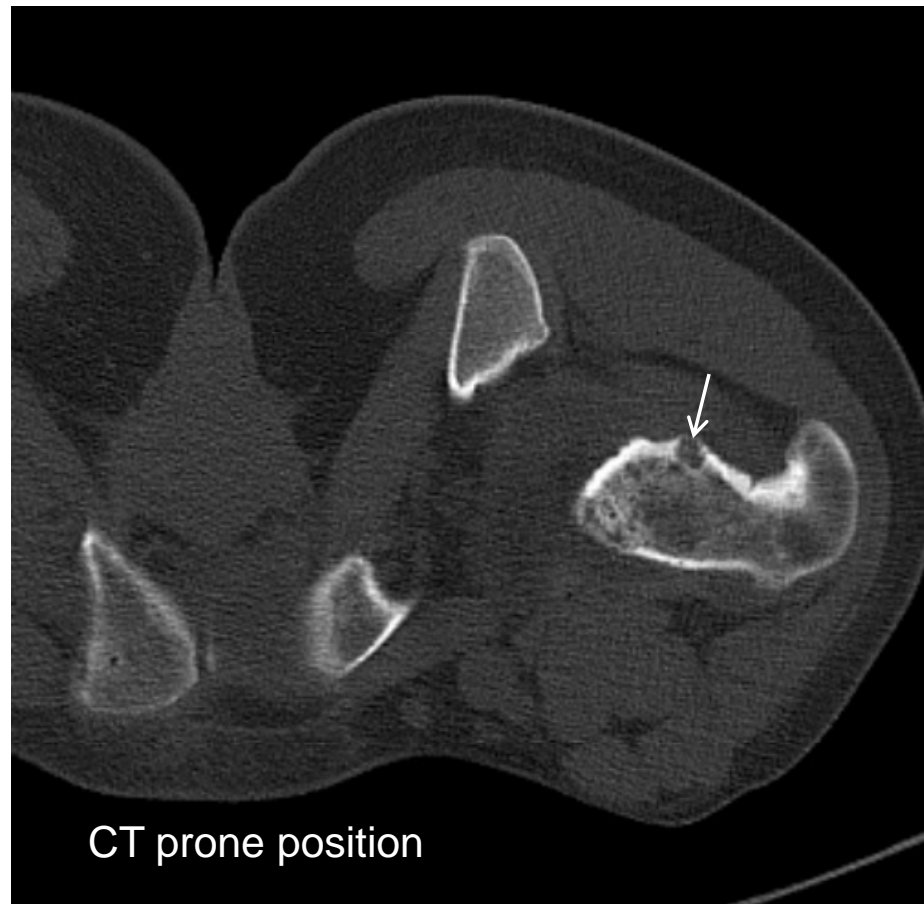


- ♀ 13 years, right hip pain for several months
- MRI: typical findings of osteoid osteoma





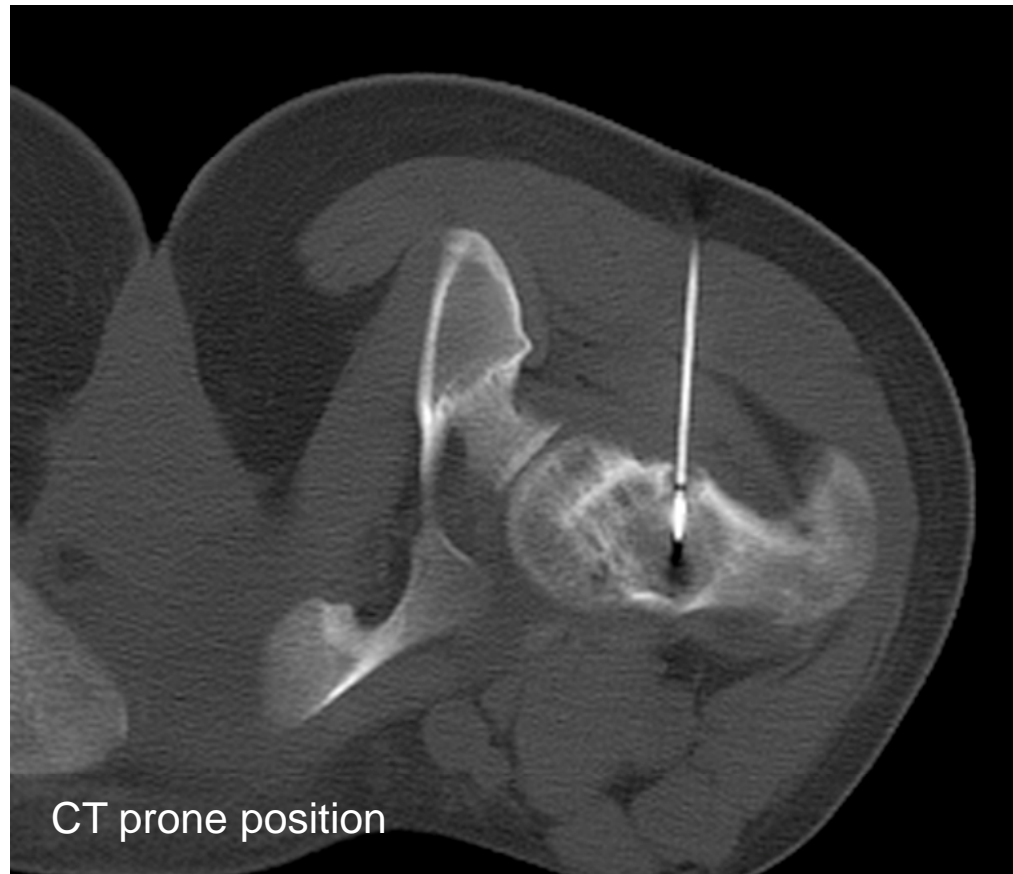
- CT: well defined osteolytic lesion in the femoral head with a thin sclerotic rim



CT prone position



- CT: Microwave-Ablation, MedWaves Ablation Probe, 16G small antenna, 16 W, 80° C, ablation time 1min





- 1 day after MW-Ablation: complete relief of pain
- Functional MRI after MW-Ablation shows a complete devascularization of the osteoid osteoma

